



**PATIENT**

Tux Warrick

**SPECIES**

Canine

**BREED**

Great dane

**SEX**

MN

**AGE**

1 year

**WEIGHT**

150 #

**INTERPRETED BY**

Remo Lobetti, BVSc,  
MMedVet (Med),  
PhD, Dipl. ECVIM

**IMAGING PERFORMED BY**

Lara Wiseman, DVM

**HOSPITAL NAME**

Fountains

**REFERRING VET**

**INVOICE**

302835

**DATE**

3/25/22

**PRESENTING CLINICAL SIGNS**

History: Urinary incontinence, chronic intermittent UTI signs that improve with antibiotics and occasionally meloxicam.

Physical Examination: N/A.

Urinalysis: N/A.

CBC: N/A.

Serum Biochemistry: N/A.

Radiographic Findings: N/A.

**ULTRASONOGRAPHIC EXAMINATION OF THE ABDOMEN**

**Urinary System**

Full urinary bladder with a normal appearance but thickened wall (0.42 cm). Normal anechoic urine with no sediment or uroliths evident.

Normal trigone area, proximal urethra, and iliac blood vessels.

Normal iliac lymph nodes. Dilated left ureter (up to 0.4 cm), right ureter not visualized.

Normal renal size (left 9.3 cm, right 9.7 cm) echogenic appearance, cortico-medullary differentiation, capsule, and right pelvis. Left pyelectasia (0.9 cm).

**Reproductive System**

Small hypoechoic prostate (1.9 cm).

**Adrenal Glands**

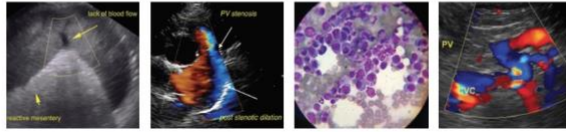
Normal shape, echogenic appearance, position, and size. Left 0.75 cm, right 0.69 cm

**Spleen**

Normal size and echogenic appearance. Smooth homogenous parenchyma, smooth curvilinear capsule, and normal vasculature. No evidence of inflammatory, neoplastic, infarction, or infiltrative changes noted.

**Liver**

Normal size, echogenic appearance, and portal markings. No nodules or masses evident. Full gall bladder containing normal anechoic bile. Normal thickness and appearance of the gall bladder wall. Normal bile duct.



**PATIENT**

Tux Warrick

**SPECIES**

Canine

**BREED**

Great dane

**SEX**

MN

**AGE**

1 year

**WEIGHT**

150 #

**INTERPRETED BY**

Remo Lobetti, BVSc,  
MMedVet (Med),  
PhD, Dipl. ECVIM

**IMAGING  
PERFORMED BY**

Lara Wiseman, DVM

**HOSPITAL NAME**

Fountains

**REFERRING VET**

**INVOICE**

302835

**DATE**

3/25/22

***Gastrointestinal***

Normal appearance of the gastro-esophageal junction, stomach, duodenum small intestine, ileo-cecal junction, and colon with no loss of layering, normal wall thickness (stomach 0.63 cm, duodenum 0.5 cm, small intestine 0.41 cm) and peristalsis, and no distension of the lumen.

***Pancreas***

Normal size (right 1.8 cm) and echogenic appearance. Regular capsule. Normal echogenic appearance of the mesentery and fat surrounding the pancreas.

***Free Abdomen***

No mesenteric lymphadenomegaly.  
No ascites.

**ULTRASONOGRAPHIC FINDINGS**

Primary findings:

- Thickened urinary bladder wall.
- Left pyelectasia.
- Dilated left ureter.

Secondary findings:

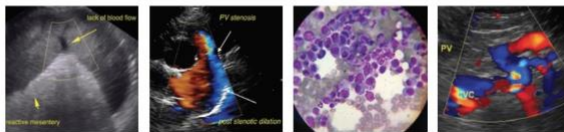
- None.

**INTERPRETATION OF THE FINDINGS & FURTHER RECOMMENDATIONS**

With the history and these ultrasound findings, the most likely etiology would be ectopic ureter with unilateral pyelonephritis a differential diagnosis. With the thickened urinary bladder wall, chronic cystitis needs to be considered.

Further assessment would be urinalysis and contrast CT of the urinary tract.

Further specific therapy would be dependent on an etiological diagnosis.



**PATIENT**

Tux Warrick

**SPECIES**

Canine

**BREED**

Great dane

**SEX**

MN

**AGE**

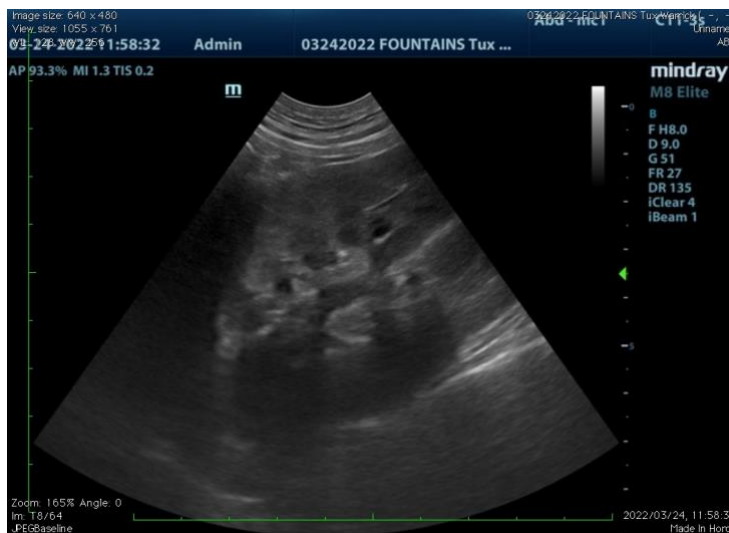1 year

**WEIGHT**

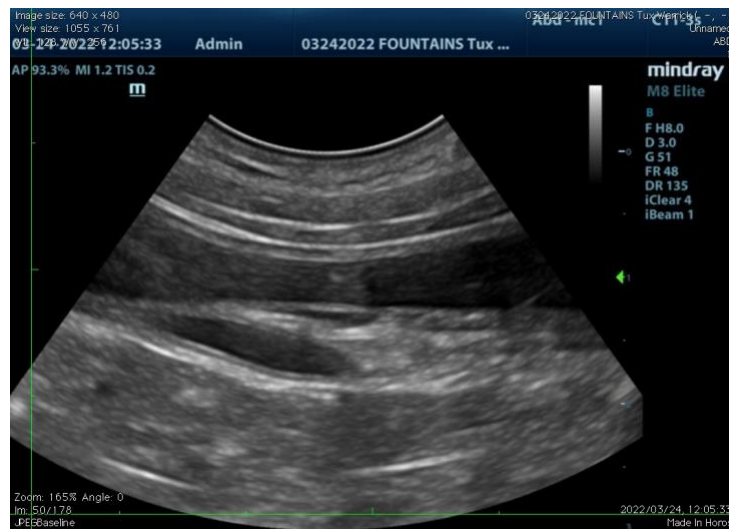150 #

**IMAGES**

**Left kidney**



**Left ureter**



**INTERPRETED BY**

Remo Lobetti, BVSc,  
 MMedVet (Med),  
 PhD, Dipl. ECVIM

**IMAGING PERFORMED BY**

Lara Wiseman, DVM

**HOSPITAL NAME**

Fountains

**REFERRING VET**

**INVOICE**

302835

**DATE**

3/25/22

The information and recommendations provided are based on the images presented by the referring veterinarian. No evaluation can be communicated regarding pathology that was not visible in the image/video clips provided.

Thank you for this referral. If the clinical or image interpretation does not parallel your findings or if I can be of any further assistance please contact me.

**Remo Lobetti, BVSc, MMedVet (Med), PhD, Dipl. ECVIM (Internal Medicine)**  
 rlobetti@mweb.co.za